Journal of Neurological Research and Therapy

Open Access - Peer-Reviewed - ISSN 2470-5020

Portico Archived | Crossref DOI | CC BY 4.0 Licensed

Short Communication

Reversible Cerebral Lession and Irreversible Cerebral Necrosis After Cardiorespiratory Arrest: A Case Report

Dao-Ming. Tong.[1*], Ye-Ting. Zhou.[2], Xiao-Dong. Chen[1]

[1] Department of Neurology, Affiliated Shu Yang People′s Hospital, XuZhou Medical University, Jiangsu, China

[2] Department of Medical research, Affiliated Shu Yang People′s Hospital, XuZhou Medical University, Jiangsu, China

*** Correspondence:** Dao-Ming Tong, Department of Neurology, Affiliated Shu Yang People's Hospital, XuZhou Medical University, No. 9 Yingbin Road, Shuyang, Jiangsu, China.

Published citation: Dao-Ming. Tong., Ye-Ting. Zhou., Xiao-Dong. Chen (2015) **Reversible Cerebral Lession and Irreversible Cerebral Necrosis After Cardiorespiratory Arrest: A Case Report**. *Journal of Neurological Research and Therapy* - 1(2):1-4. https://doi.org/10.14302/issn.2470-5020.jnrt-15-701

Article DOI: 10.14302/issn.2470-5020.jnrt-15-701

Keywords:
Cerebral Necrosis; Cardiorespiratory Arrest; Cerebral Lesions

Article Information	
Running Title	cerebral lession after cardiorespiratory arrest
Academic Editor	Biswarup Ghosh, Thomas Jefferson University, Dept. of Neuroscience, Philadelphia, US
Received Date	20 August 2015
Accepted Date	20 December 2015
Published Date	28 December 2015
Online	28 December 2015
Publication	Volume 1; Issue 2; Pages 1–4
Copyright	© 2015 Dao-Ming Tong, et al.
License	This is an open-access article distributed under the terms of the Creative Commons Attribution License, which permits unrestricted use, distribution, and reproduction in any medium, provided the original author and source are credited. https://creativecommons.org/licenses/by/4.0/

Introduction

The differences in functional outcomes and pathological findings after brain damage from cardiorespiratory arrest are not widely appreciated. Computed tomographic (CT) scan and magnetic resonance imaging (MRI) may provide insights into the mechanisms and distributions of early brain injury. We report one patient with classic post-resuscitation encephalopathy (PRE) from severe hypoxia or ischemia, whose prognosis correlated well with CT and MRI findings.

Case Report

A 46-year-old woman was found in cardiorespiratory arrest after she had an out-of-hospital an suddenly drop stroke lasting about 27 min. She was successfully resuscitated and admitted to the intensive care unit. The etiopathogenesis of cardiac arrest was ventricular fibrillation for the patient. On initial examination, her pupils were 2 mm in diameter and nonreactive to light, and there was unresponsiveness to external stimulation, and the score on the Glasgow Coma Scale was 3(E1V1M1). On admission, initial head CT revealed no significant findings. On the three days after onset, a repeat noncontrast CT images showed a whole cerebral brain swelling, caudal transtentorial herniation, and microhemorrhages in the intercerebral and subarachnoid (Figure 1A). Diffusion-weighted magnetic resonance imaging (DWI) performed on day 14 showed extensive lesions of the bilateral middle, hippocampus and the gray matter of the frontal and temporal cortices (Figure 1 B). In addition, brain MRI T2-weighted imaging showed bilateral symmetric high signal intensity in the caudate, putamen, thalami, occipital, parietal cortices

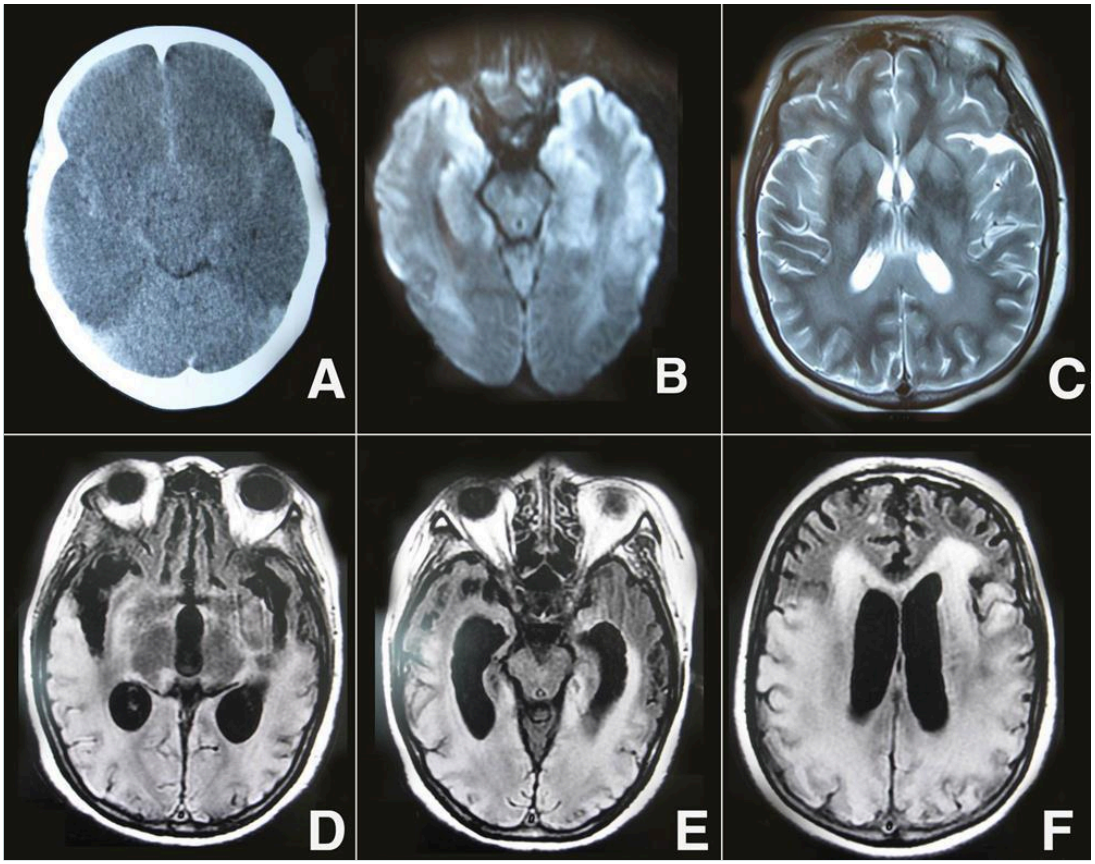

Figure 1. A) Brain CT showed a whole cerebral brain swelling, caudal transtentorial Herniation, and microhemorrhages in the intercerebral and subarachnoid; B) DWI showed extensive lesions of the bilateral middle, hippocampus and the gray matter of the frontal and temporal cortices; C) brain MRI T 2-weighted imaging showed bilateral symmetric high signal intensity in the caudate, putamen, thalami, occipital, parietal cortices and subcortical white matter; D-F) On follow-up MRI 60 days later, FLAIR showed cortical, subcortical white matter, and periventricular white matter confluent hyperintense lesions in the bilateral temporal, parietal, and occipital regions, and enlarged ventricles.

and subcortical white matter (Figure 1C). After 20 days, her neurological status was improved, the GCS scale was 8 (E4V1M3). she did not show any signs of conscious perception regarding the different types of stimulation, including pain. She had been in a vegetative state. On follow-up MRI 60 days later, Fluid-attenuation inversion recovery image (FLAIR) showed cortical, subcortical white matter, and periventricular white matter confluent hyperintense lesions in the bilateral temporal, parietal, and occipital regions, and enlarged ventricles (Figure 1D-F). After three months, she did not perform requested commands and displayed spastic palsy to a higher extent in the lower limbs. The GCS scale was 9 (E4V1M4), and she was declared to be in a persistent vegetative state.

Discussion

Post-Resuscitation Encephalopathy (PRE) is a relatively frequent condition. PRE is introduced as a term to describe the comatose state after CPR.[1] The prognosis of CPR is different, depending on whether the brain damage is reversible or irreversible. Our patient was confirmed that early CT scan of CPR may not have abnormal changes, and upon to the 2-3 days later she had obvious diffuse edema and minor intercerebral hemorrhages. Therefore, the monitoring of the diffuse edema and mimic minor hemorrhages on brain CT is useful for an early diagnosis of PRE. However, most studies have confirmed that MRI is more useful for predicting prognosis than CT scan. On day 14 after onset, DWI showed extensive lesions of the bilateral middle, hippocampus, caudate, putamen, thalami, occipital, parietal and the gray matter of the frontal and temporal cortices. Previous studies indicated that presence of a lesion pattern of multilobar, or diffuse, cortical involvement, termed as "extensive cortical lesion pattern", and associated with poor outcome. [2,3] In fact, on day 20 after onset, the patient's neurological status was improved, and her GCS scale was 8 (E4V1M3). Moreover, on follow-up MRI 60 days later, the hyperintense lesions in the bilateral frontal, thalami, and middle have been reversed, suggesting some cortical and subcortical cerebral lesions were reversible. However, periventricular white matter confluent hyperintense lesions in the bilateral temporal, parietal, and occipital regions have not been reversed, suggesting these hyperintense lesions were irreversible. An earlier study has shown that patients with bilateral basal ganglia, thalami, and/or substantia nigra lesions may survive in a persistent vegetative state (PVS).[4] Current MRI-FLAIR found that patients with bilateral temporal, parietal, and occipital extensive lesions may also survive in a PVS.

According to the diagnostic criteria of persistent vegetative state published by the American Academy of Neurology in 1995, our patient with a persistent vegetative state has been diagnosed. Our study suggests that these delayed high signals on DWI or FLAIR from PRE represent an irreversible neuronal necrosis and atrophy practically. This has also been confirmed by an earlier study.[5]

DWI and FLAIR imaging may help overcome this problem when treating physicians and family members require more information on prognosis. However, the potential of MRI to complement examination based predictions of outcome and to select target populations most likely to benefit from treatment strategies needs further study.

Disclosures

None.

Competing Interests

The authors have declared that no competing interests exist.

References

1. Maramattom B V, EFM Wijdicks. Post resuscitation encephalopathy. Current views, management and prognostification. 2005. *Neurologist* 11:234-243
2. Topcuoglu MA, Oguz KK, Buyukserbetci G, Bulut E.Prognostic Value of Magnetic Resonance Imaging in Post-Resuscitation Encephalopathy. *Inter Med*.2009;48:1635-1645. https://doi.org/10.2169/internalmedicine.48.2091
3. Hirsch KG, Mlynash M,Eyngorn I,Pirsaheli R, Okada A, et al Multi-Center Study of Diffusion-Weighted Imaging in Coma After Cardiac Arrest. *Neurocrit Care*.2015 Jul 9. [Epub ahead of print]

4. Fujioka M, Okuchi K, Sakaki T, Hiramatsu K, Miyamoto S, Iwasaki S. Specific changes in human brain following reperfusion after cardiac arrest.*Stroke*. 1994;25:2091-2095. https://doi.org/10.1161/01.str.25.10.2091

5. Wu O, Sorensen AG, Benner T, Singhal AB, Furie KL, Greer DM.Comatose patients with cardiac arrest: predicting clinical outcome with diffusion-weighted MR imaging. *Radiologe* 2009;252:173-81. https://doi.org/10.1148/radiol.2521081232

Publisher's Note

All claims, opinions, data, and conclusions expressed in this article are solely those of the author(s) and contributor(s), and do not necessarily represent those of Open Access Pub, the journal, its editors, or reviewers. Open Access Pub does not guarantee or endorse any product, method, instruction, or claim discussed in the article, and disclaims responsibility for any injury to people or property resulting from ideas, methods, instructions, or products referred to in the content.