

Metastatic Malignant Melanoma of the Gastrointestinal Tract: A Rare Case and Review of Current Literature

Julian Iñaki L. Garcia^{1,*}, Jennielyn C. Agcaoli-Conde², Dexter Santos³

¹Gastroenterology Fellow, De La Salle University Medical Center

²Gastroenterology-Hepatology, De La Salle University Medical Center

³Medical Oncology, De La Salle University Medical Center

Corresponding author:

Julian Iñaki L. Garcia, Gastroenterology Fellow, De La Salle University Medical Center

Keywords:

Malignant Melanoma, Gastrointestinal Tract, Metastasis

Received: Feb 08, 2022

Accepted: Mar 05, 2022

Published: Mar 14, 2022

Editor:

Carlo Aprile, IRCCS Fond. Policlinico San Matteo - Pavia-Italy

Abstract

Malignant melanoma the most common malignancies associated with GI involvement. They usually manifest clinically at an advanced stage of neoplasm. Surgery is also recommended for palliative treatment of GIT metastases.

A case of a 67-year-old male diagnosed with malignant melanoma for 7 months had

burning epigastric pain and bloatedness. Esophagogastroduodenoscopy showed multiple flat lesions. Biopsy findings were consistent with malignant melanoma.

Malignant melanoma has an early tendency to metastasize and has a high mortality rate due to its complications. In patients with malignant melanoma since Gastrointestinal involvement is now being documented as part of metastatic work up esophagogastroduodenoscopy is suggested as an important tool in the treatment and patient's +outcome. Although metastases to the stomach is rare, it is essential to be thorough and include an upper endoscopy to rule out metastatic disease, especially in symptomatic patients.

Introduction

Malignant melanoma is the most serious type of skin cancer and it develops from pigment-producing cells known as melanocytes. This neoplasm has a five-year survival rate between 3 to 19% depending on the location and number of metastases. Melanomas typically occur in the skin but may occur in the mouth, intestines or eyes, and

rarely, inside the body, such as nose or throat^[1].

Malignant melanoma is one of the most common malignancies associated with gastrointestinal (GI) involvement^[1]. The incidence is 43.5% and is most commonly seen in the liver, peritoneum, pancreas, small bowel, spleen colon, stomach, oral cavity and esophagus^[1]. Although the incidence of GI metastasis is less frequent compared to the skin, lung and brain, this usually manifests clinically at an advanced stage of neoplasm^[7].

Esophagogastroduodenoscopy is performed in symptomatic patients in order to rule out the disease. Gastrointestinal (GI) melanomas are unusual and once its presence is noted, it requires thorough investigation.

Surgery improves the survival rate significantly in patients with metastatic melanoma to the GI tract, especially when the resection is considered complete following microscopic examination. The median survival after complete resection is 48.9 months, compared with 5.4 months after an incomplete resection. Surgery is also recommended for palliative treatment of GI metastases, with symptom relief reported in the range of 77% to 100% of patients, depending on the site and the reason for resection^[5,6,7].

Case Report

This is a case of a 67-year-old male who presented with a burning sensation in the epigastric area and complained of bloating one month prior to admission. Patient was diagnosed with malignant melanoma with lymph node involvement and pulmonary metastasis 7 months prior to his symptoms. Patient had several episodes of nausea, vomiting and bloatedness; thus, he was referred to the gastroenterology service for further work-up and management. There was no associated weight loss or hematochezia. His family history for cancers was unremarkable. Patient had completed 13 episodes of radiotherapy and this was associated with epigastric burning pain and bloatedness.

In the interim, he had an esophago-gastroduodenoscopy which showed multiple flat lesions

seen at the body (Figure 1a), antrum (Figure 1b) and at the duodenum (Figure 1c and 1d). Biopsy samples were taken and they showed epithelial cells disposed singly and in nests invading the gastric mucosa. These biopsy findings were consistent with malignant melanoma. Besides melanin nodules, only erosive gastritis with no ulcers was noted.

During this admission, the patient was given a proton pump inhibitor, calcium carbonate and simethicone to address underlying gastrointestinal symptoms, which prompted improvement of the epigastric burning pain, bloatedness and nausea. Immunotherapy was initiated with pembrolizumab which the patient tolerated without any adverse reactions.

Unfortunately, the patient had also been diagnosed with Hospital-Acquired Pneumonia (HAP) with pulmonary effusion noted in both lungs. Chest tube thoracotomy was done and antibiotics were shifted. The patient improved and was subsequently, discharged.

Discussion

Malignant melanoma that involves the GI tract may either be primary or metastatic. Primary GI melanoma can arise in various GI mucosal sites, including the oral cavity, esophagus, small bowel, colon, rectum and anus in the absence of prior cutaneous melanoma^[1]. Distinguishing between a primary GI mucosal melanoma and a melanoma metastatic to the GI tract from an unknown or regressed cutaneous primary may be difficult. The most common subtype of melanoma, superficial spreading melanoma, is the most common subtype to metastasize to the GI tract although all histological subtypes of cutaneous melanoma may metastasize to the GI tract^[1,2].

Concerning the anatomic site of gastric metastases, the majority of these are reported to occur in the body and in the fundus of the stomach, most often in the greater curvature with lesions in the lesser curvature being very uncommon^[3]. In our patient the lesions were located at the body (Figure 1A), and at the antrum (Figure 1B), as also seen at the duodenal bulb and the second

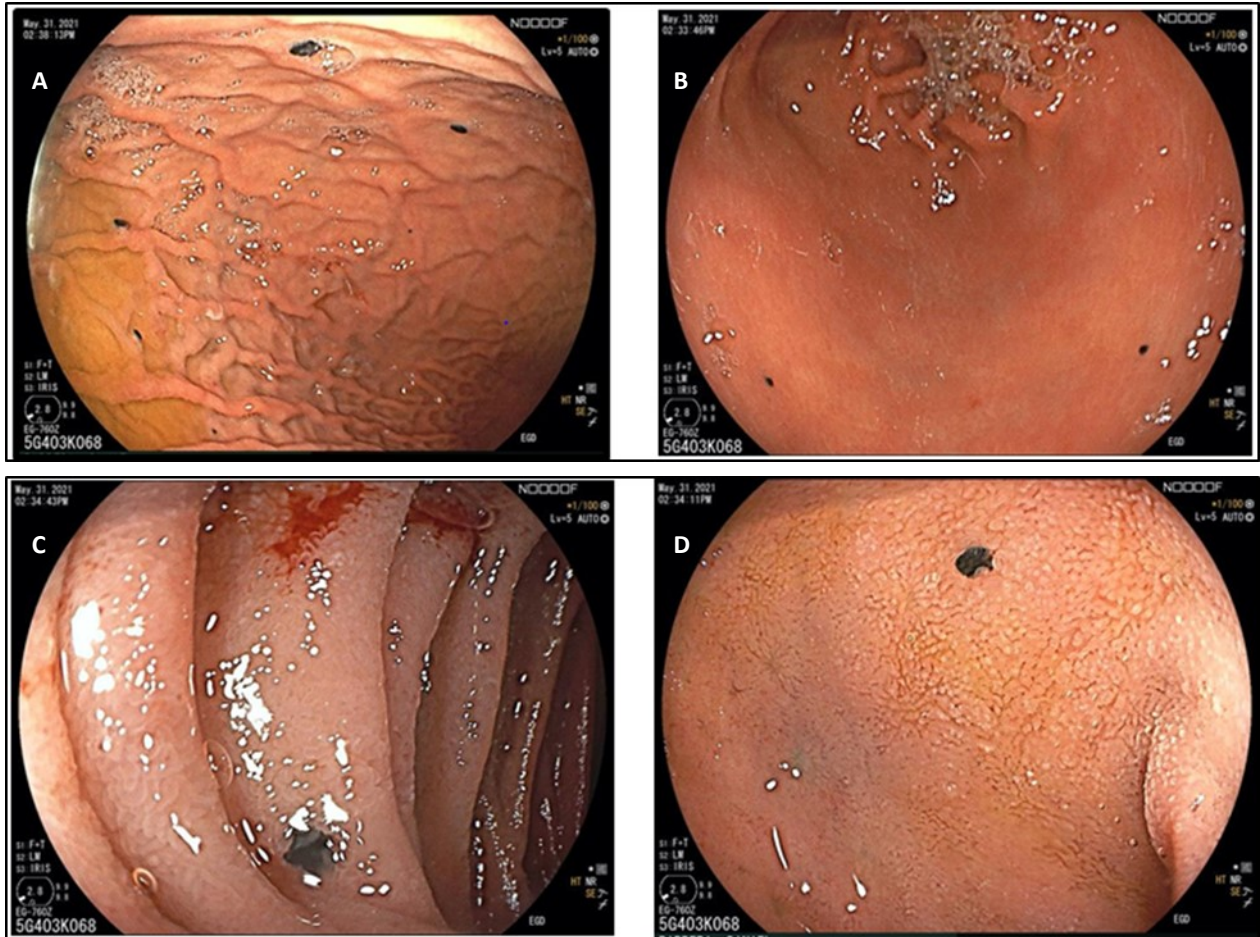


Figure 1. (A) Antrum (B) Gastric body (C) 2nd part of the Duodenum (D) Duodenal bulb

portion (Figure 1C and 1D). CT scans showed metastases noted on the lungs, mediastinal lymph nodes and right hepatic lobe.

Malignant melanoma of the gastric is mostly asymptomatic and it explains why it largely eludes detection. Symptoms include nausea, vomiting, gastrointestinal bleeding, weight loss and acute perforation^[3]. In our patient, he showed nausea, vomiting and bloatedness which was medically controlled. EGD shows only erosive gastritis with no ulcers noted.

The endoscopic classification of gastric metastases comprises three main morphological types. First, melanotic nodules often have an ulcerated tip. Secondly, there are submucosal tumor masses which are elevated and ulcerated at the apex. Third, morphological type is a mass lesion with varying incidence of necrosis and melanosis. In our patient he had the first morphological type^[3,4].

The prognosis of patients with metastatic malignant melanoma is poor. Studies suggest a mean survival of patients with systemic metastases from melanoma to be only 6 to 8 months^[1]. Treatment of metastatic melanoma GI tract may include surgical resection, chemotherapy, immunotherapy and observational trials. The immunocompromised state may cause serious complications in patients with GI tract involvement.

Conclusion

Malignant melanoma has an early tendency to metastasize and has a high mortality rate due to its complications; thus, assessment of metastasis is important and is vital in the treatment and patient's outcome. Although metastases to the stomach is rare, it is essential to be thorough and include an upper endoscopy to rule out metastatic disease, especially in symptomatic patients.

References

1. Liang KV, Sanderson SO, Nowakowski GS, Arora AS. Metastatic malignant melanoma of the gastrointestinal tract. *Mayo Clin Proc.* 2006 Apr;81(4):511-6. doi: 10.4065/81.4.511. PMID: 16610571.
2. Simons M, Ferreira J, Meunier R, Moss S. Primary versus Metastatic Gastrointestinal Melanoma: A Rare Case and Review of Current Literature. *Case Rep Gastrointest Med.* 2016;2016:2306180. doi: 10.1155/2016/2306180. Epub 2016 Aug 29. PMID: 27651960; PMCID: PMC5019918.
3. El-Sourani N, Troja A, Raab HR, Antolovic D. Gastric Metastasis of Malignant Melanoma: Report of a Case and Review of Available Literature. *Viszeralmedizin.* 2014 Aug;30(4):273-5. doi: 10.1159/000364814. PMID: 26288600; PMCID: PMC4513808.
4. Wong K, Serafi SW, Bhatia AS, Ibarra I, Allen EA. Melanoma with gastric metastases. *J Community Hosp Intern Med Perspect.* 2016;6(4):31972. Published 2016 Sep 7. doi:10.3402/jchimp.v6.31972
5. Augustyn A, de Leon ED, Yopp AC. Primary gastric melanoma: case report of a rare malignancy. *Rare Tumors.* 2015;7(1):5683. Published 2015 Mar 27. doi:10.4081/rt.2015.5683
6. Genova P, Sorce M, Cabibi D, Genova G, Gebbia V, Galanti D, Galanti D, Ancona C, Valerio MR. Gastric and Rectal Metastases from Malignant Melanoma Presenting with Hypochromic Anemia and Treated with Immunotherapy. *Case Rep Oncol Med.* 2017;2017:2079068. doi: 10.1155/2017/2079068. Epub 2017 Oct 12. Erratum in: *Case Rep Oncol Med.* 2018 Feb 27;2018:3142394. Galanti, Daniela [corrected to Galanti, Daniele]. PMID: 29158932; PMCID: PMC5660775.
7. Alghisi F, Crispino P, Cocco A, Richetta AG, Nardi F, Paoluzi P, Badiali D. Morphologically and immunohistochemically undifferentiated gastric neoplasia in a patient with multiple metastatic malignant melanomas: a case report. *J Med Case Rep.* 2008 Apr 30;2:134. doi: 10.1186/1752-1947-2-134. PMID: 18445301; PMCID: PMC2396655.