

## Late Onset Meningitis In Post Traumatic Temporal Meningoencephalocele

Zahra Sadr<sup>1</sup>, Samileh Noorbakhsh<sup>2,\*</sup>, Nazanin Zafaranloo<sup>3</sup>, Fereshteh Moshfegh<sup>4</sup>, Yaser Nasoori<sup>5</sup>

<sup>1</sup>Fellowship in pediatric infectious diseases, Iran University of Medical and Sciences, Tehran, Iran.

<sup>2</sup>Professor of Pediatric Infectious Disease, pediatric infectious diseases Department, Iran University of Medical Sciences. Tehran, Iran.

<sup>3</sup>Pediatrician, Clinical Researcher, Iran University of Medical and Sciences, Tehran, Iran.

<sup>4</sup>Pediatrician, Department of Neonatology, Iran University of Medical and Sciences, Tehran, Iran.

<sup>5</sup>ENT and Head & Neck Research Center and department, Iran university of medical and sciences

### Corresponding author:

Samileh Noorbakhsh, Department of Pediatric Infectious Diseases, 4th floor Rasul Akram Hospital, Niayesh Street, Satarkhan Avenue, Tehran, 14455 Islamic Republic of Iran

DOI: 10.14302/issn.2997-1977.jd-22-4183

### Keywords:

bacterial meningitis, meningoencephalocele, temporal lobe

**Received:** May 06, 2022

**Accepted:** May 24, 2022

**Published:** May 31, 2022

### Abstract

Temporal lobe meningoencephalocele is an uncommon anomaly in the face. As brain tissue herniate through the dural imperfection, cerebrospinal fluid (CSF) or a mass will appear in the mastoid, middle ear or the both. Here we present a 10 years old boy with right lobe temporal

meningoencephalocele which results in CSF leakage and manifested with bacterial meningitis. He had a history of head trauma and bone fracture 3 years ago. In surgery the defect repaired and the patient showed improvement.

### Introduction

Meningitis is an inflammation of the brain membranes and spinal cord. Bacterial meningitis etiology has been changed in recent decade due to H. Influenza (HIB), S. pneumonia and Meningococcal vaccination [1,2]. It has different risk factors such as; head trauma, immune suppression, central nervous shunts, cerebrospinal fluid fistula/leak, neurological diseases, alcoholism, sinusitis, otitis media, pharyngitis, bacterial pneumonia, sickle cell disease, and congenital defects, age, social factors, exposures to pathogens, immunocompromising factors and drug usage [3-7] cerebrospinal fluid analysis and culture is the best way for meningitis diagnosis. Some of the most complications that are associated with meningitis is; brain edema,

hydrocephalus, infarcts, cerebral herniation and focal infection. They all need cranial CT scan for diagnosis [8].

An encephalocele is a rare congenital neural tube defect. It happens when brain tissues protrude through a hole in the skull. Temporal bone encephaloceles manifest either as a mass or cerebrospinal fluid (CSF) in the middle ear or mastoid or both. Temporal lobe encephalocele is a rare disease. It is estimated about 1/3000 to 1/35000[9]. There are two main etiologies for the temporal lobe encephalocele; acquired (traumatic fracture, radiation, erosions, tumors, etc.) and congenital skull base defects [10]. Temporal lobe encephalocele does not have any specific signs and symptoms; so the diagnosis is with delay most of the time. The patient should expect a lot of complications such as seizures, abscess, meningitis and venous infarction, if remain untreated.

### Case Report

A 10 years old boy was referred to Rasul Akram Hospital (tertiary hospital) in Tehran, Iran. The clinical presentation was headache, vertigo, and intermediate coughs for one week. The frontal and bitemporal headache intensified by head bending, just one-time fever before admission. He received Co-amoxiclav and diphenhydramine in out-patient. There wasn't any pain relief by using the drugs and due to the headache worsening and vomiting he was taken to the clinic for serum therapy. His drug was changed to azithromycin. The day after serum therapy he had delirium and gradually leads to loss of consciousness (LOC), was intubated in first hospital, then referred and admitted in PICU of Rasool Akram hospital. In the admission day, he had a fever (39/1), pulse rate=114, respiratory rate=17, blood pressure=116/76. Pupils were in normal size and had reaction to light and his deep tendon reflexes (DTR) were decreased, no kerning or Brudzinski sign. Course crackles in both lungs and downward Babinski reflexes were found in his examination. He was self-extubated about four hours after admission to PICU and was oxygenated by nasal cannula without any decrease in O<sub>2</sub> saturation.

### Previous History

Three years ago, he had a severe head trauma and skull fracture during car accident and was in coma for 3 months. He gradually improved better and could walk and speak after speech therapy, physiotherapy and occupational therapy.

### Findings

Aspiration pneumonia had found in chest CT scan. In addition to blood culture and other laboratory tests, Lumbar puncture had done (without any contraindication in brain Ct scan) CSF analysis determined bacterial meningitis. All the serial laboratory tests showed in Table 1.

High dose of Cefotriaxone (100 mg/kg/day) and vancomycin (20mg/kg/q6h) were started. Dexamethasone (0.6 mg/kg/day), Phenytoin (5mg/kg/day/BD), Acyclovir (10mg/kg/dose/TDS) and pneumococcal vaccine, were added. He was clearly alert at second day of admission, and he was transferred to the pediatric ward at third day. His abdominal Sonography was normal. A fracture on the right roof of the right tympan and soft tissue density in the middle ear suggestive cholesteatoma reported in Brain Ct scan on day of admission (Photograph 1).

Despite the abnormal manifestation in mastoid cells, the audiometric examination was normal. Due to continuing the headache and right ear, the spiral HRCT of temporal bone without injection was requested. (photograph 2)

After ten days of treatment, lumbar puncture (LP) was done again which was absolutely normal and his headache relieved more than before. He was discharged, for further visit by ENT and neurosurgeon. Subsequently, after 2 weeks he was admitted by ENT service and was operated. That was an interesting result which was meningoencephalocele of right temporal lobe with CSF leak as detailed below.

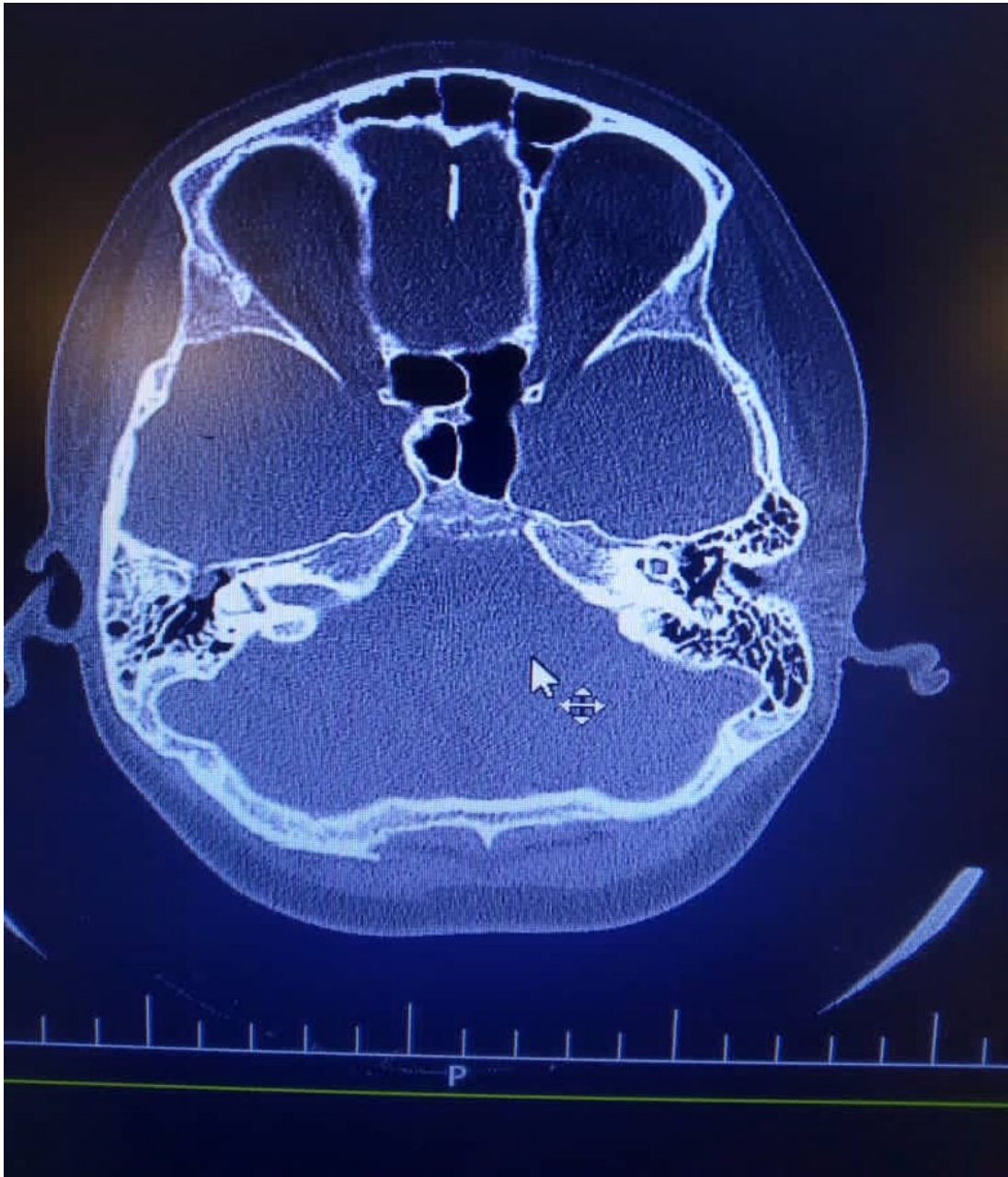
ENT surgeon reported: A craniotomy opening is made in the squamous portion of the temporal bone and is approximately 5 cm by 5 cm. This bone flap is based on the root of the zygoma with care to avoid laceration of the

Table 1. Results for serial laboratory tests

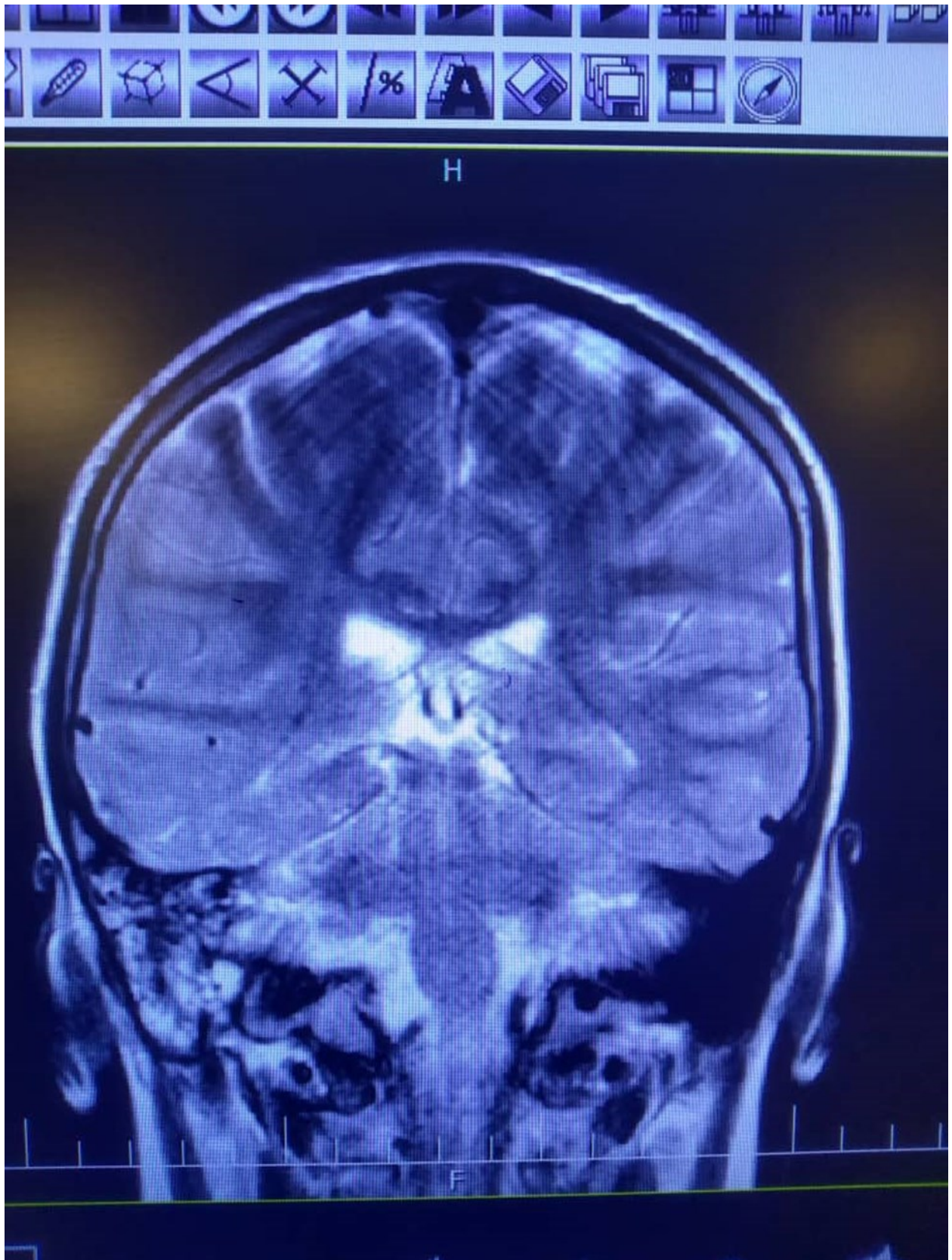
WBC	25800	Neut:86%	Lym:14%				
	7880	Neut:57%	Lym:31%				
	6100						
	6100	37%	43%				
RBC	4/14	4/83	4/5				
Hb	12	13/9	13	12/7			
Hct	35/5	38	39				
MCV	29	80	86				
MCHC	33	35	33				
Plt	226000	280000	405000	253000			
ESR	31	74	59				
CRP	>48	>48	12				
BS	77		82				
Na	136	142	147				
K	4/8	4/4	3				
Ca	11/3	10/9	10/6				
P	2/7	4/6	4/5				
Mg	2/7	2/2	1/7				
AST	9						
ALT	19						
ALK	375						
BUN	9	14	8				
Cr	0/7	0/8	0/8				
CPK	985						
LDH	1151	519					
FERRITIN	142	122					
LP	Wbc:6400	Rbc:1260	GLU:55	Pro:210	LDH:240	Neut:90%	Lym:10%
	10	10	53	13	42		10%
CSF/C	negative	Negative					
U/A	SG:1017	WBC:10	RBC:30	Pro:+1	Blood:+4	Bacteria: moderate	
	SG:1030	WBC:1-2	RBC:0-1	Pro:-	Blood:-		
U/C	negative	Negative					
B/C							
PT	14/6						
PTT	29						
INR	½						
D-dimer	1317						
ABG	PH:7/38	PCO2:44	PO2:27	HCO3:26	BE:1/2		
Covid-19	PCR	IgM:0/63	IgG:10/33				

### Abbreviations

WBC: White Blood Cell / RBC: Red Blood Cell / Neut: Neutrophil / Lym: lymphocyte / Hb: Hemoglobin / Hct: Hematocrit / MCV: Mean Corpuscular Volume / MCHC: Mean Corpuscular hemoglobin concentration / Plt: Platelet / ESR: erythrocyte sedimentation rate / CRP: C-reactive protein / BS: Blood Sugar / Na: Sodium / K: Potassium / Ca: Calcium / P: phosphor / Mg: Magnesium / AST: Aspartate Transaminase / ALT: Alanine Transaminase / ALK: Anaplastic lymphoma kinase / BUN: Blood urea nitrogen / Cr: Creatinine / CPK: Creatine phosphokinase / LDH: Lactate dehydrogenase / Ferritin: Ferritin / LP: Lumbar puncture / CSF/C: Cerebrospinal Fluid/Culture / U/A: Urine Analysis / B/C: Blood culture / PT: Prothrombin time / PTT: Partial thromboplastin time / INR: International Normalize Ratio / D-dimer: a fibrin degradation product / ABG: Arterial Blood Gas / COVID-19: Coronavirus Disease-2019



Photograph 1. There is evidence of fracture on the right roof of the right tympan. Slight opacity of right mastoid air cells is evident. There is soft tissue density in the middle ear and epitympan and preusak cavity suggestive cholesteatoma.



Photograph 2. High signal intensity in both hemispheres is noted suggestive of meningitis. In T2 sequence there are hyper signal material left maxillary sinus and bilateral frontal sinuses in favour of sinusitis, polyp and retention cyst in left maxillary sinus is noted. Effusion in right mastoidal air cell is noted.

underlying dura. The dura is elevated from the floor of the middle fossa. Venous bleeding was controlled with absorbable knitted fabric (Surgical) Dissection of the dura proceeds in a posterior-to-anterior manner. When the dura has been elevated with blunt Dural elevator, the House-Urban retractor was placed on the edge of a bone. The location of the bone defect was observed in anterior medial tegment tympani. The part of the brain tissue that was inside the middle ear was removed. To repair the defect, first a layer of fascia and then a piece of bone was placed on the fascia. Due to the presence of CSF leakage, another layer of fascia was extradural placed on the site of perforation and fixed on the perforated area with the help of fibrin glue. The field is inspected for hemostasis, and the middle fossa retractor is removed, the bony flap was fixed in place by suturing it to the surrounding bones. A mastoid dressing completes the closure.

Our case was visited 2 and 6 months after his surgery without any complications and he had normal hearing.

## Discussion

An encephalocele usually happens when brain tissue herniates through a dural defect of the skull. Temporal bone encephaloceles show either as a mass or cerebrospinal fluid (CSF) in the middle ear or mastoid or both.

Cerebrospinal fluid otorrhea and temporal lobe encephaloceles (TLEs) including the tegmen tympani also mastoid are infrequent. neurotologic conditions that have become more common in the past 10 years. [11]

Cerebrospinal fluid otorrhea and TLE come with serious aftermaths such as meningitis and brain abscesses, including conductive hearing loss and chronic middle ear effusion. [12]

All temporal bone CSF usually occur through the tegmen (tympani or mastoideum) and through the temporal lobe dura. Posterior fossa plate that leak over the cerebellum are not common. [13]

CSF leaks that are secondary to head trauma are

well documented. It usually resolves spontaneously or with lumbar drainage within 1 to 2 weeks after the incident. [14]

Usually, Preparatory radiographic evaluation begins with a high-resolution computed tomography (CT) of the skull base. A magnetic resonance imaging (MRI) study is helpful to display for the presence of an encephalocele and may confirm that the effusion has a similar signal characteristic as CSF. If CT and MRI are non-diagnostic, other imaging formats such as a radionuclide cisternogram study could be helpful. [15] The gold standard confirmatory test for a CSF fistula is the presence of beta-2 transferrin in the fluid that was used as a sample. [16]

A more frequent discovery is a soft compressible mass in the mastoid cavity coming off the tegment that may mimic a blue dome cyst or cholesterol granuloma. [17] Less frequent presentations include meningitis and seizures [18, 17].

## Conclusion

MRI is the gold standard technique for detecting brain tissue herniation in middle ear cavities. The involved tissue is shown as a mass iso-intense in all sequences in MRI. Hypo intense in T1 and hyper intense in T2 with diffusion weighted sequences [25] is seen in cholesteatoma and cholesterol granuloma appears hyper- intense in both T1 and T2. Administration of contrast only will show granulation tissues [24].

CT scan is the other technique for diagnosis. It is so much important to detect the size and location of the involved bones with high resolution computer tomography; but there is a defect with that which cannot detect the solidarity of soft tissues. It has limitation in detecting granulation, cholesteatoma, cholesterol granuloma or other soft tissue masses inside the middle ear cavity. [19,20,21,22,23]

Different surgical techniques now are available. Repairing the whole layers (bone and soft tissue) is

more effective than the only repair in soft tissue, due the increased risk of recurrence [25,26].

Middle cranial fossa craniotomy (MCF), trans mastoid and combined MCF/trans mastoid are one of the surgical techniques for temporal bone CSF-L which reduces the risk of meningitis, conductive hearing loss and otorrhea [27].

### Abbreviations

CSF: Cerebrospinal Fluid

HIB: Hemophilus Influenza

PICU: Pediatric Intensive Care Unit

DTR: Deep Tendon Reflexes

LP: Lumbar Puncture

MRI: Magnetic Resonance Imaging

HRCT: High Resolution Compound Tomography

ENT: Otorhinolaryngology

GCS: Glasgow Coma Score

### Ethics Approval and Consent to Participate

NA

### Consent for Publication

NA

### Availability of Data and Materials

NA

### Funding

There is no Funding

### Conflict of Interest

The authors have no conflict of interest to declare.

### Acknowledgements

NA

### References

- Schuchat A, Robinson K, Wenger JD, et al. Bacterial meningitis in the United States in 1995. Active Surveillance Team, *N Engl J Med*, 1997, vol. 337 (pg. 970-6)
- Dawson KG, Emerson JC, Burns JL. Fifteen years of experience with bacterial meningitis, *Pediatr Infect Dis J*, 1999, vol. 18(pg. 816-22)
- Geiseler PJ, Nelson KE, Levin S, Reddi KT, Moses VK. Community-acquired purulent meningitis: A review of 1,316 cases during the antibiotic era, 1954-1976. *Rev Infect Dis*. 1980;2(5):725-45. [PubMed: 6763303].
- Chavez-Bueno S, McCracken GH Jr. Bacterial meningitis in children. *Pediatr Clin North Am*. 2005;52(3):795-810. vii. doi: 10.1016/j.pcl.2005.02.011. [PubMed: 15925663].
- Mace SE. Acute bacterial meningitis. *Emerg Med Clin North Am*. 2008;26(2):281-317. viii. doi: 10.1016/j.emc.2008.02.002. [PubMed: 18406976].
- Schutze GE, Mason EO Jr, Barson WJ, Kim KS, Wald ER, Givner LB, et al. Invasive pneumococcal infections in children with asplenia. *Pediatr Infect Dis J*. 2002;21(4):278-82. [PubMed: 12075756].
- Porto I. *Acute bacterial meningitis*. US Pharmacist; 2012. Available from: [http://www.uspharmacist.com/continuing\\_education/ceviewtest/lessoned/108112/](http://www.uspharmacist.com/continuing_education/ceviewtest/lessoned/108112/).
- Van de Beek D, de Gans J, Spanjaard L, Weisfelt M, Reitsma JB, Vermeulen M. Clinical features and prognostic factors in adults with bacterial meningitis. *N Engl J Med*. 2004; 351(18): 1849-59. doi: 10.1056/NEJMoa040845. [PubMed: 15509818].
- Golding-Wood DG, Williams HO, Brookes GB. Tegmental dehiscence and brain herniation into the middle ear cleft. *J Laryngol Otol* 1991; 105:477-80.
- Lalwani AK, Jackler RK, Harsh GR 4<sup>th</sup>, Butt FY. Bilateral temporal bone encephaloceles after cranial irradiation. Case report. *J Neurosurg* 1993; 79:596-9.
- Nelson RF, Gantz BJ, Hansen MR: The rising incidence of spontaneous cerebrospinal uid leaks in the United States and the association with obesity and obstructive sleep apnea. *Otol Neurotol* 36:476-480, 2015
- Raine C: Diagnosis and management of otologic cerebro- spinal uid leak. *Otolaryngol Clin North Am* 38:583-595, 2005

13. Kutz JW Jr, Johnson AK, Wick CC. Surgical management of spontaneous cerebrospinal fistulas and encephaloceles of the temporal bone. *Laryngoscope* 2018; 128:2170–2177
14. Savva A, Taylor MJ, Beatty CW. Management of cerebrospinal fluid leaks involving the temporal bone: Report on 92 patients. *Laryngoscope*. 2003; 113: 50–56.
15. Reddy M, Baugnon K. Imaging of cerebrospinal fluid rhinorrhea and otorrhea. *Radiol Clin North Am* 2017; 55:167–187.
16. Warnecke A, Averbek T, Wurster U, Harmening M, Lenarz T, Stover T. Diagnostic relevance of beta2-transferrin for the detection of cerebrospinal fluid fistulas. *Arch Otolaryngol Head Neck Surg* 2004; 130:1178–1184.
17. Graham MD. Surgical management of dural and temporal lobe herniation into the radical mastoid cavity. *Laryngoscope*. 1982; 92:329–331.
18. Ferguson BJ, Wilkins RH, Hudson W. Spontaneous CSF otorrhea from tegmen and posterior fossa defects. *Laryngoscope*. 1986; 96:635–644.
19. Kenning TJ, Willcox TO, Artz GJ, Schiffmacher P, Farrell CJ, Evans JJ. Surgical management of temporal meningoencephaloceles, cerebrospinal fluid leaks, and intracranial hypertension: treatment paradigm and outcomes. *Neurosurg Focus* 2012;32(6):E6.
20. Sanna M, Fois P, Paolo F, Russo A, Falcioni M. Management of meningoencephalic herniation of the temporal bone: personal experience and literature review. *Laryngoscope* 2009;119(8):1579–85.
21. Carlson ML, Copeland WR, Driscoll CL, Link MJ, Haynes DS, Thompson RC, et al. Temporal bone encephalocele and cerebrospinal fluid fistula repair utilizing the middle cranial fossa or combined mastoid-middle cranial fossa approach. *J Neurosurg* 2013;119(5):1314–22.
22. Souliere CR, Langman AW. Combined mastoid/middle cranial fossa repair of temporal bone encephalocele. *Skull Base Surg* 1998;8(4):185–9.
23. Leonetti JP, Marzo S, Anderson D, Origitano T, Vukas DD. Spontaneous transtemporal CSF leakage: a study of 51 cases. *Ear Nose Throat J* 2005;84(11):700, 702–4, 706.
24. Bovo R, Ceruti S, Padovani R, Martini A. Temporal bone brain herniation. *Otol Neurotol Off Publ Am Otol Soc Am Neurotol Soc Eur Acad Otol Neurotol* 2006;27(4):576–7.
25. De Foer B, Vercruyse J-P, Bernaerts A, Deckers F, Pouillon M, Somers T, et al. Detection of postoperative residual cholesteatoma with non-echo-planar diffusion-weighted magnetic resonance imaging. *Otol Neurotol Off Publ Am Otol Soc Am Neurotol Soc Eur Acad Otol Neurotol* 2008;29(4):513–7.
26. Lundy LB, Graham MD, Kartush JM, et al. Temporal bone encephalocele and cerebrospinal fluid leaks. *Am J Otol*. 1996; 17:461–469.
27. Lobo BC, Baumanis MM, Nelson RF. Surgical repair of spontaneous cerebrospinal fluid (CSF) leaks: a systematic review. *Laryngoscope Investig Otolaryngol* 2017;2:215–224.